

28555-Article_Text-91433-1-10- 20220811.pdf

by

Submission date: 12-Aug-2022 12:21PM (UTC+0700)

Submission ID: 1881638398

File name: 28555-Article_Text-91433-1-10-20220811.pdf (460.33K)

Word count: 5496

Character count: 28116

Exposure to old formaldehyde compounds of liquid air freshener products on lung, heart and brain cell histology of mice (*Mus musculus*)

Delima Engga Maretha^{1*}, Asnilawati², Vina Prisunarti Putri², Senja², Tri Ayu², Muhammad Mustapha Adam³

¹Department of Biology, Faculty of Science and Technology, Universitas Islam Negeri Raden Fatah Palembang Jl. Prof. K. H. Zainal Abidin Fikri No. KM. 3, RW. 5 Kemuning, Palembang, South Sumatera, Indonesia. 30126

*Email: delimaenggamaretha_uin@radenfatah.ac.id

²Department of Biology Education, Faculty of Tarbiyah and Teacher Training, Universitas Islam Negeri Raden Fatah Palembang

Jl. Prof. K. H. Zainal Abidin Fikri No. KM. 3, RW. 5 Kemuning, Palembang, South Sumatera, Indonesia. 30126

³Department of Chemistry, Faculty of Science, Gombe State University Gombe State University, P.M.B 127, Tudun Wada Gombe, Gombe State, Nigeria. 760214

ABSTRACT. Air freshener is a product commonly used to reduce unpleasant odors. Air freshener contains compounds containing chemicals such as terpenes, aldehydes (formaldehyde), ethanol, phenol, linalool, citronellol, naphthalene, dibutyl phthalate (DBP), diisobutyl phthalate (DIBP), diisohexyl phthalate (DIHP) and 1,4 dichlorobenzenes (benzene). The purpose of this study was to determine the effect of exposure to liquid air freshener on the histology of alveolus, heart muscle, and brain in mice (*Mus musculus*). The design of this research was to use a post-test-only control group design. The post-test was done by observing the histology of the alveoli, heart muscle, and brain. After exposure to air freshener liquid as much as 3 ml 3 times a day for 6 weeks. The research subjects were 20 mice that were 2 months old. The data were tested using One Way ANOVA statistical test followed by post hoc Tukey. The results showed that air freshener had an effect on the alveoli (alveolar septum), the heart in the form of thinning of the heart muscle and there was a change in the thickness of the brain layer. Based on the research, it can be concluded that liquid air freshener affects the histology

Keywords: air freshener; alveolar histology; environmental pollution; heart and brain; *Mus musculus*

Article History: Received 19 March 2022; Received in revised form 10 April 2022; Accepted 15 May 2022; Available online 30 June 2022. Ver: Pre-Press

How to Cite This Article: Maretha DE, Asnilawati A, Putri VP, Senja S, Ayu T, Adam MM. 2022. Exposure to old formaldehyde compounds of liquid air freshener products on lung, heart and brain cell histology of mice (*Mus musculus*). *Biogenesis: Jurnal Ilmiah Biologi*. vol 10(1): 121–129. doi: <https://doi.org/10.24252/bio.v10i1.28555>.

INTRODUCTION

Air freshener is a product that is quite improved in society. Air fresheners have a potentially hazardous health impact, including the occurrence of sensory and respiratory irritation and lung disorders. Air fresheners can react with ozone to produce secondary pollutants, such as formaldehyde and secondary organic aerosols (SOA). Oxidative products and ultrafine particles. These pollutants harm human health in many ways, such as damage to the central nervous system, changes in hormone levels, etc. In particular, ultrafine particles can cause damage to various organs such as the lungs and cardiovascular (Kim *et al.*, 2015).

Air fresheners are composed of toxic chemicals that include limonene, aldehyde, benzene & toluene. When these chemicals are emitted, chemical reactions of volatile organic compounds in air fresheners with ozone change rapidly & produce potentially biohazard intermediates such as formaldehyde & oxidative products & proceed to form secondary pollutants which cause adverse health effects (Kim *et al.*, 2015). Yuningtyaswari & Athika (2016) found out that air freshener exposure at early age have a bad influence on the liver cells of white rat. Alshaer *et al.* (2019) discovered some toxic chemicals in a sample of air freshener; linal, galaxolide, benzenemethanol, musk ketone, butylated hydroxytoluene, and linalool capable of causing irritation and other health problems which were not revealed in the product's label. Hence, need to be free of toxic pollutants.

Chemicals contained in air fresheners can affect pulmonary function, namely Volatile Organic compounds (VOC) and phthalates. Formaldehyde is part of the VOC compound which is a compound that is harmful to pulmo. Formaldehyde can cause inflammation and can cause oxidative stress in

pulmonary tissue. (2-ethylhexyl) phthalate (DEHP) is a phthalate derivative that can cause inflammation in the pulmonary alveoli due to oxidative stress. Phenol is a chemical that can cause chronic inflammation¹³ body systems, such as irritation to the eyes, skin, respiratory tract, and mucous membranes. The most common reasons for chronic inflammation include autoimmune disorders, such as lupus, where your body attacks healthy tissue. Exposure to toxins, like pollution or industrial chemicals. Untreated acute inflammation, such as from an infection or injury. The presence of certain social, psychological, environmental and biological factors has been linked to the prevention of resolution of acute inflammation and, in turn, the promotion of a state of low-grade, non-infective (sterile) systemic chronic inflammation (SCI) that is characterized by the activation of immune components that are often distinct from those engaged during an acute immune response (Furman *et al.*, 2019).

This manuscript investigates the effect of liquid air freshener exposure on the histology of alveoli, cardiac muscle, and brain in mice, which could offer an unanticipated and undiscovered risk. It addresses the scientific and health perspectives, and it can provide policy direction to reduce the use of harmful liquid air fresheners.

17

MATERIALS AND METHODS

This research was conducted at the Laboratory of Animal House Abduh Center Palembang and Special Laboratory of Anatomical Pathology Dyatnitalis Palembang. This type of research is quantitative research. This research was conducted under a post-test-only control group research design. Consisting of three treatment groups and one control group with five replications with the following details: Control group without treatment, P1 was given 3 ml of air freshener three times a day for two weeks, P2 was given 3 ml of air freshener three times a day for four weeks, and P3 was given 3 ml of air freshener three times a day for six weeks.

Experimental animals. The mice used were 2 months old before being treated. First, the mice were acclimatized for 7 days at the Animal House Abduh Center Palembang. The mice were taking place in the close cage that the air only from some hole from the cage.

Determination and preparation of air freshener treatment doses. Repeat doses were used in this study in accordance with what the research had done. In rabbits, it is 1ml/kg BW. The dose will be used for experimental animals (mice) by converting and calculating the dose conversion based on the rabbit to mouse dose conversion table (Laurence *et al.*, 2008). For liquid air freshener, exposure is done with a spray bottle.

Grouping of test animals. Samples of 20 male mice were divided into control group (K) and treatment group (P0, P1, P2 and P3). Each group consisted of 5 mice. The dosage of air freshener are 3ml/3 days, P1 for two weeks, P2 for four weeks and P3 for six weeks.

Organ (alveolus), heart and brain isolation. Mice were dissected 1 day after being given the last treatment. All mice were killed by being anesthetized using chloroform, then the blood was cleaned using the perfusion method and then the alveoli, heart and brain were taken. Then the organs were put into a fixative, namely formalin, for making histological preparations. The parameters that observe were the tissue of alveolar of lung, cardiac muscle and cerebrum from the brain of mice. Fix tissue in 10% neutral buffer formaldehyde (NBF) solution or freshly prepared 4% paraformaldehyde solution. Formaldehyde-based fixatives are preferred for long term tissue preservation and are known to produce best results for sectioning, morphology (H&E), special stains and immunohistochemistry. Tissue was cut into smaller pieces (max. 4-5 mm), tissue is completely immersed in the fixative. Fixation must be performed for no more than 24-36 h depending on the size of tissue. Timing of the exposure of a sample to the fixative was important and must be calibrated. Fixed tissue should be transferred to PBS or 70% ethanol and sent for processing to prepare tissue blocks.

Histological preparation. Preparation was using the paraffin block method, with the hematoxylin eosin (He) staining technique. Tissues processed into paraffin will have wax in the cassettes; in order to create smooth wax blocks, the wax first needs to be melted away placing the

entire cassette in 58°C paraffin bath for 15 minutes. Turn the heat block on to melt the paraffin one hour before adding the tissue cassettes. Cassette opened to view tissue sample and choose a mold that best corresponds to the size of the tissue. A margin of at least 2 mm of paraffin surrounding all sides of the tissue gives best cutting support. Discard cassette lid. Put small amount of molten paraffin in mold, dispensing from paraffin reservoir. Using warm forceps, transfer tissue into mold, placing cut side down, as it was placed in the cassette. Transfer mold to cold plate, and gently press tissue flat. Paraffin will solidify in a thin layer which holds the tissue in position. When the tissue is in the desired orientation add the labeled tissue cassette on top of the mold as a backing. Press firmly. Hot paraffin is added to the mold from the paraffin dispenser. Be sure there is enough paraffin to cover the face of the plastic cassette. If necessary, fill cassette with paraffin while cooling, keeping the mold full until solid. Paraffin should solidify in 30 minutes. When the wax is completely cooled and hardened (30 min) the paraffin block can be easily popped out of the mold; the wax blocks should not stick. If the wax cracks or the tissues are not aligned well, simply melt them again and start over. After the paraffin block process, the staining with the hematoxylin eosin (He) staining technique (Sari, 2015). The Organ that was observe the change of histology, the thickness of the tissue each from alveolar, cardiac and cerebrum. For histology parameters of this research to examine distension (widening) and destruction of the septum. Heart muscle in the treatment group, the occurrence of damage was marked by thickening, bleeding and necrosis. The histology of the brain is characterized by thinning of the cerebrum layer of the brain.

Microscopic observation. Histological observations were made on cross sections of the alveolus, heart and brain for each treatment. From each slide, five visual fields were taken randomly starting from the top left counterclockwise (Olympus CX21) with an objective magnification of 40x10. The photo results were then analyzed with the Image raster program to count of the change in each organ, this process was carried out blindly.

RESULTS AND DISCUSSION

Alveolar histology results. The results of this study observed the histological appearance of the alveoli in mice (*Mus musculus*) males with *Swiss webster* strain which were treated with exposure to liquid air freshener showed changes and differences. Microanatomical structure of the alveoli from several treatment groups the effect of liquid air freshener on the histological picture of the alveoli in mice (*Mus musculus*). It can be seen in the Fig 1.

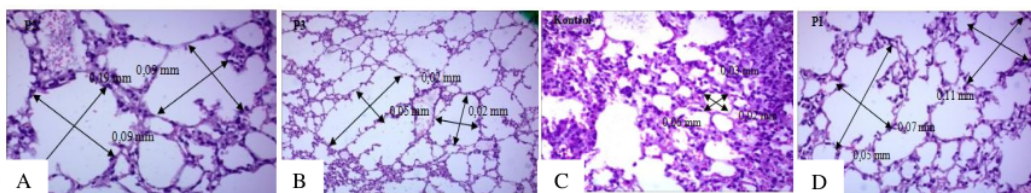


Fig. 1. HE coloring 40x10 magnification, Olympus CX21: A. P0; B. P1; C. P2; D. P3.

Fig. 1 in treatment P0 (without treatment). Normal criteria, in P1 treatment, there were changes in the alveolus cells marked by widening and a little septal destruction compared to P0 treatment. In treatment P2 it was very clear that the cells were damaged, namely distension and treatment three (P3), it was very clear that there was thinning between the cell walls (septal destruction) signs of damage that could trigger emphysema. Alveolar cell changes with increased loosening of the alveolar septum. Shows changes in the alveolar septum that is thinning. Shows that liquid air freshener has an effect on the alveoli. Based on the changes that occur, then the test is carried out. That is normality test using descriptive analysis, then the homogeneity of variances test was continued. Effect of exposure liquid air freshener in the alveolar of Lung, P2 have the highest effect from P1 and P3 showed changed from every weeks observation, we can observe the data from Table 1 dan Fig. 2. The thickness of the alveolar septal interstitium increased linearly with the increase in radius of

curvature of alveoli. The increase in interstitial thickness in lungs with larger alveoli was paralleled by large increases in the volume of collagen and elastin fibers present in this space. Comparable changes in the thickness of connective tissue fibers in alveolar duct walls were also found.

Table 1. Mice alveolar septum thickness.

Groups	Septum thickness (mm)			Average
	I	II	II	
P0	0.06	0.02	0.03	0.03
P1	0.07	0.05	0.11	0.07
P2	0.09	0.19	0.09	0.12
P3	0.05	0.02	0.02	0.03

According to Table 1, it is known that liquid air freshener affects the thickening of the alveoli significantly ($P=0.04$). This means that liquid air freshener can affect the alveolar of lung. Therefore, further tests were carried out to see the effect between treatments as Tukey post hoc test, affected but not significantly ($P=0.66$) each group (Table 2).

Table 2. ANOVA and Tukey's HSD test.

ANOVA test	ANOVA test					Tukey's HSD			
	Sum of Squares	df	Mean Square	F	Sig	Groups	n	$\alpha = 0,05$	
Source of Variance								1	2
Between Groups	017	3	006	4.444	041	P3	3	03000	
Within Groups	010	8	001			P0	3	0367	0367
Total	027	11				P1	3	0767	0767
						P2	3		1233
						Sig		422	066

Cardiac histology. In this study, changes in the histology of the heart of mice in the form of thinning of cardiac muscle tissue. This observation uses a microscope with a magnification of 40×10 . Measurement of cardiac muscle tissue with 3 fields of view. The microanatomical structure of the heart muscle from each treatment shows in Fig. 2.

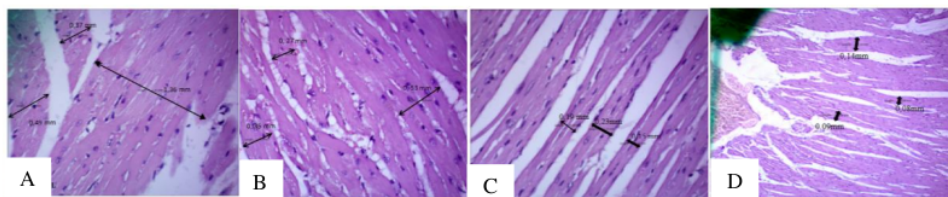


Fig. 2. Cardiac muscle histology 40x10 magnification: A. P0; B. P1; C. P2; D. P3.

According to Table 3, it is known that liquid air freshener affects the thickening of the heart muscle of mice significantly. Tukey post hoc test was conducted as Table 4.

Table 3. Mice heart muscle thickness.

Group	Heart muscle thickness (mm)			Average
	I	II	II	
P0	0.37	0.49	1.36	0.74
P1	0.35	0.27	0.53	0.38
P2	0.19	0.23	0.15	0.19
P3	0.09	0.08	0.14	0.10

Table 4. ANOVA and Tukey's HSD test.

ANOVA test					Tukey's HSD					
Source of Variance	Sum of Squares	df	Mean Square	F	Sig.	Groups	n	$\alpha = 0,05$		
Between Groups	1.079	3	360	10.580	0.004	P3	3	1	2	3
Within Groups	272	8	0.34			P0	3	-0.9976		
	1.351	11				P1	3	-0.7278	-0.7278	
						P2	3		-0.4334	-0.4334
Total				10.580	0.004	P2	3			-0.2027
						Sig.		0.343	0.280	0.463

Brain histology. Based on the results that have been obtained from the research, it can be seen that there is a change, namely the impact that is shown, namely the thinning of the cerebrum layer of the mouse brain. By using a raster image application and changes observed with a microscope with a magnification of 40x10 with 3 fields of view, there are differences in each treatment group as presented in Fig 3.

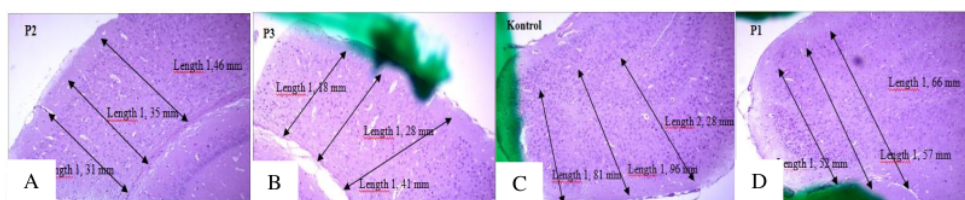
**Fig. 3.** Histology of mice brain magnification 40x10: A. P0; B. P1; C. P2; D. P3.

Table 5 shown that liquid air freshener affects the thickening of the lining of the brain in mice significantly. Tukey post hoc test was conducted as seen in Table 6.

Table 5. The thickness of the lining of the brain in mice (*Mus musculus*)

Groups	I	II	III	Average
P0	1.81	2.28	1.96	2.01
P1	1.57	1.52	1.66	1.58
P2	1.46	1.31	1.35	1.37
P3	1.28	1.41	1.18	1.29

Table 6. ANOVA and Tukey's HSD test.

ANOVA test					Tukey's HSD					
Source of Variance	Sum of Squares	df	Mean Square	F	Sig.	Groups	n	$\alpha = 0,05$		
Between Groups	0.950	3	0.317	15.449	0.001	P3	P3	1	2	
Within Groups	0.164	8	0.020			P0	P2	3		0.2900
	0.114	11				P1	P1	3		0.3733
						P2	P0	3		0.5833
Total	0.950	3	0.317	15.449	0.001	P2	P0	3		
						Sig.	Sig.			0.133

From the observation of the alveoli, it is seen that there is a decrease in distension, for the alveolar septum it is very clear to experience changes, namely the thinning of the cell wall with other cell walls. The septal destruction in the P2 group was very high compared to the P1 and P3 groups. From the difference in values from the average table 1, it can be influenced by the presence of chemical compounds in liquid air fresheners. When these chemical compounds (radicals) react with cells, they will cause lipid peroxidation, membrane protein damage and DNA damage. Lipid peroxidation causes a decrease in the fluidity of the membrane in the function of the membrane barrier, causing cell death or cell apoptosis.

Exposure to particles that concentrate in the air in the short and long term can cause pulmonary inflammation in mice (*Mus musculus*). Such as the presence of emphysema which is defined as a widening of the alveoli, alveolar ducts and the loss of the boundary wall between the alveoli and then the widening of the alveoli due to cell death or cell apoptosis in the alveolar walls. Meanwhile, destruction of the alveolar septum is damage to the alveolar walls in which there is damage to the protein elastin and collagen of the epithelial membrane, which is marked by the thinning, atrophy of the alveolar septum, and in some places, there is total damage to the alveolar septum (interalveolar septum) which forms a round shape (Dewi *et al.*, 2015).

Cell damage that occurs in the alveoli indicates that exposure to air fresheners made from benzene derivatives has toxic properties due to the chemicals contained in liquid air fresheners. So that the damage that occurs is not only seen in the alveolar structure which experiences distension (widening), and destruction of the alveolar septum but also causes emphysema, so that if exposed to liquid air fresheners with active ingredients such as benzene derivatives, phenols, ethanol, limonene, aldehydes, the longer the exposure, the longer the exposure. alveolus widening and cell death.

Exposure to benzene has a harmful effect on the physiology of the respiratory system. Several studies have found the carcinogenic effect of benzene exposure which can affect the epithelial cells that line the respiratory system, bronchioles and alveoli causing a decrease in lung function (Susantiningsi *et al.*, 2014). As the results of research by Yuningtyas & Haryani (2015), the chemical 1,4-dichlorobenzene (benzene) enters the alveolus through the inhalation route, this inhalation is an important exposure route for toxic chemicals. Inhaled toxic substances make up most of the cells lining the alveoli (type I and type II cells). Aerosols that settle mainly in the upper respiratory tract. The distance or depth of penetration will increase as the aerosol size decreases, most of which will collect in the lower airways. The deposited particles will be cleaned by a mucociliary mechanism. Aerosols larger than 1 can reach the alveoli. Alveolus aerosol will be absorbed into the blood system or cleaned by immune cells (macrophages) which will enter these particles. Acute exposure can cause inflammation and decreased alveolar function. The presence of distension (widening) and destruction of the alveolar septum is thought to occur due to the influence of air fresheners that damage proteins and elastin fibers and other components in the alveolar septum. Alveolus exposed to air freshener show damage to emphysema caused by distension and destruction of the septum.

An imbalance of oxidants and antioxidants in the body that can cause oxidative stress and trigger an inflammatory reaction, for locally exposed alveolar tissue. The inflammatory process can result in pulmonary macrophages and infiltration of neutrophils which will cause inactivation of antiproteases, namely 1-AT, as a proteinase inhibitor in the lungs by making or producing pulmonary elastase. This can damage the protein structure of the lung. Process through destruction of the alveolar septum. The elasticity of the lung parenchyma tissue is disturbed, such as changes in the structure and function of the lung tissue (Rohmani, Nur and Aulia, 2018).

The results of the acquisition of the observed parameters showed that there was a change marked by the presence of alveolar distension (widening) and destruction of the alveolar septum. Damage to the alveoli with increasing dose. The control value was always better than the P1, P2 and P3 treatments because the control was without air freshener and the control was used as a comparison for the treatment. The presence of distension (widening) and destruction of the septum which causes the alveoli to be damaged will result in cell death or cell apoptosis. Observations on the heart organ on the effect of liquid air freshener in the control treatment showed normal, in the P1 treatment the heart muscle tissue was slightly thinned, in the P2 and P3 treatment it showed that the heart muscle tissue in the mice was getting thinner and there was necrosis (damage to cells).

Judging from the difference in thickness values, it may be influenced by chemical compounds contained in liquid air fresheners that can affect the performance of the heart muscle. Chemical compounds present in air freshener can affect the thickness of heart muscle tissue and can cause necrosis in the group exposed to the air freshener which was thinner than the control group (P0) without exposure to the air freshener. Several studies have shown that air freshener has a direct toxic

effect on the heart muscle is phenol. Heart damage due to this phenol as a result of hypoxia as well as damage to cells. Phenol is a free radical that can oxidize nucleic acids, causing damage and cell death. Phenol compounds can also interfere with oxygen transport to the muscle mitochondria in the myocardium layer by binding to myoglobin which can cause oxidative stress in heart muscle cells so that it can cause cell death. Cell death in the form of necrosis or apoptosis is characterized by changes in typical cell nuclei, namely pyknosis, karyorexia, and karyolysis. Nuclei that undergo pyknosis will shrink, dark in color, irregular boundaries and clumping of chromatin occurs on hematoxylin-eosin (HE) staining to become basophilic (Tursinawari, 2017). The result of this research showed changed from histology that the tissue thickness because the toxic effect from liquid air freshener.

According to Damayanti (2016), chemicals can cause changes to cell function and cells become damaged and die, so cells will adapt. The cell response can be reversible, i.e. the cell undergoes morphological changes but the cell does not die. One form of cell adaptation response is atrophy. Whereas the process of cell adaptation in which the organ or tissue that is formed grows to reach normal limits but then experiences shrinkage. If there is an infection of the heart muscle, it can affect the need for oxygen and nutrients needed by the whole body. This infection can cause cell death in the form of necrosis and apoptosis of heart muscle through oxidative stress and inflammation mechanisms. Physiological changes that occurred in mice after the exposure was finished showed different reactions after each treatment. Mice (*Mus musculus*) will experience a loss of appetite for a while after spraying, mice will drink more, and look less active or look weak. Another condition is that mice scratch their bodies more often.

Air fresheners are said to be the main contributor to poor indoor air quality with a risk factor ranging from 2.7%. The use of air fresheners is used to cover unpleasant odors, with the aim of creating a pleasant taste in the room. Even so, the presence of chemical substances contained in air fresheners can interfere with air quality. The content in air fresheners contains volatile organic compounds, which can stimulate the olfactory nerve. Along with its use, it is increasingly being used at home and other public facilities (Afighor *et al.*, 2019). The weakness of air freshener products produced by factories or synthetic air fresheners is their high chemical content, so it can be said that these products are not environmentally friendly and have a bad impact on human health that is exposed (Dewa & Mozes, 2014). One of them was proven in the study of Steinemann, *et.al* (2020), which showed that there were 133 VOCs (Volatile Organic Compounds) released by 25 samples of air freshener products which were classified into toxic, dangerous and carcinogenic compounds.

¹⁸ The brain is the most important organ because it is an organ that has a coordinating function. Failure of brain development will result in disruption of almost all body functions because the formation of brain organs is the earliest to be formed, but finishes its formation last (Irnidayanti *et al.*, 2010). This tendency to decrease brain weight is also thought to be caused by a decrease in overall development. Abnormalities of brain development, especially in the cerebrum in the form of thinning of the cerebral cortex at 13 days is a time of very rapid cerebrum development, so that if there are toxic substances that enter the brain, it will affect the thickness of the brain layer (Setiawan *et al.*, 2013). In the early stages of brain development, the brain is not yet covered by a protective membrane. The protective membranes of the fetal brain and liver are more permeable to chemicals. In addition to being caused by the death of neuroepithelial cells, a decrease in brain weight or a decrease in the size of the cerebrum is also caused by a decrease in the number of brain cells that are able to proliferate or a decrease in protein due to inhibition of DNA and RNA synthesis (Setiawan *et al.*, 2013). Prolonged contact with the use of air freshener can cause side effects on health such as neurobehavioral disorders and an increase in oxidative stress that can change in the exposed mouse brain (*Mus musculus*) and can cause behavioral changes, memory loss, anxiety and can disrupt the dopaminergic system. The mechanism underlying neurobehavioral disorders caused by exposure to chemicals contained in air fresheners (Umukoro *et al.*, 2019).

The process of entering or detecting a chemical substance or odor that can reach the brain starting from the sense of smell. In this case the compound will be able to enter through the nasal cavity then

will walk into the olfactory gap and will bind to the olfactory receptors on the olfactory epithelium (Fjaeldstad, 2018). The mechanism by which ethanol induces brain neuronal apoptosis is still unclear, but the neurotoxic effects mediated by increased oxidative stress may be due to ethanol. Many studies have shown the neurotoxic effect of ethanol on the central nervous system, both mature and developing. Damage due to ethanol in adult brain organs or causes cognitive deficits such as learning and memory disorders (Yunus & Dwi, 2012).

Several studies have linked it to oxidative stress which induces the formation of free radicals that cause cell damage and cell death. Low concentrations of antioxidants can cause brain tissue to be susceptible to damage by oxidative stress. The cerebellum and hippocampus are the parts of the brain that are most susceptible to damage by oxidative stress because they have low antioxidant activity. Further research can examine molecular base of the tissue from mechanism of receptor to prevent the tissue from the damage of air freshener, regeneration of the cell, apoptosis pathway.

CONCLUSION

It can be concluded that effect of exposure to liquid air freshener on the histological picture of the alveoli (alveolar septum) in the treatment group showed a marked damage with distension (widening) and destruction of the septum. For histology of heart muscle in the treatment group, the occurrence of damage was marked by thickening, bleeding and necrosis. The histology of the brain is characterized by thinning of the cerebrum layer of the brain. P3 is the group that most shows signs of septal destruction, and damage to the heart muscle is characterized by thickening, bleeding and necrosis. The thinning of the cerebrum layer of the brain is caused by the effects of air freshener exposure.

ACKNOWLEDGEMENTS

The authors would like to thank the Dyatnatalis Laboratory, Animal House Abduh Center and Integrated Laboratory of Islamic State University Raden Fatah.

REFERENCES

- Afghor M, Benneth BA, Abayomi MA, Solomon U. 2019. Role of cytochrome c and tumor necrosis factor-alpha in memory deficit induced by high doses of a commercial solid air freshener in mice. *Journal of Chemical Health Risks*. vol 9(4): 263-274. doi:http://doi.org/ 10.22034/JCHR.2019.669291.
- Bernhard D, Wangs XL. 2007. Smoking oxidative stress and cardiovascular diseases-do anti-oksidative therapies fai. *Curr. Med*. vol (14): 1703-12. doi:http://doi.org/ 10.2174/092986707781058959.
- Damayanti OM. 2016. Uji keamanan karbon aktif dan kemampuannya untuk mengurangi kerusakan jaringan respirasi akibat indoor pollution. [Skripsi]. Yogyakarta: Universitas Muhammadiyah Yogyakarta.
- Dewi SC, Sudiastuti S, Rudy AN. 2015. Pengaruh lama pemaparan obat anti nyamuk kertas berbahan aktif transfluthrin terhadap struktur histopatologi pulmo mencit (*Mus musculus*). *Jurnal Bioprospek*. vol 10(2): 31-35.
- Dewa RP, Mozes SYR. 2014. Pengaruh perendaman KOH 5% terhadap rumput laut sebagai bahan baku produk gel pengharum ruangan. *Biopropal Industri*. vol 5(2).
- Dikshith TSS, Diwan PV. 2003. Industrial guide to chemical and drug safety. John Wiley & Sons: New Jersey. Hal. 229-230.
- Fjaeldstad A. 2018. Testing olfactory function and mapping the structural olfactory networks in the brain. *Danish Medical Journal*. vol 5(2): 234-239.
- Furman, D., Campisi, J., Slavish, G.M. 2019. Chronic inflammation in the etiology of disease across the life span. *Nat Med*. 2019 December; 25(12): 1822–1832. doi:10.1038/s41591-019-0675-0.
- Herman R. 2009. *Buku ajar fisiologi*. Jilid 1. Penerbit Buku Kedokteran EGC:-. Hal. 1, 2, 910.
- Irnidayanti Y, Win D, Agus A. 2020. Ekspresi level gen mRNA protein ekstraseluler otak embrio mencit block-6 UK-12 akibat induksi 2-methoxyethanol: Analisis secara real time RT-PCR. *Jurnal Berk*. vol 15(2): 171-179.
- Kim S, Seong-Ho H, Choon KB, Myuang HC. 2015. Characterization of air freshener emission the potential health effects. *Jurnal of Toxicological Sciences*. vol 4(5): 535-550. https://doi.org/10.2131/jts.40.535
- Pontel, L. B. et al. Endogenous formaldehyde is a hematopoietic stem cell genotoxin and metabolic carcinogen. *Mol. Cell* 60, 177–188 (2015). DOI:10.1016/j.cotox.2018.07.001
- Rohmani A, Noor Y, Aulia AR. 2018. Rokok elektrik dan rokok konvensional merusak alveolus paru. Prosiding Seminar Nasional Unimus. -. E-ISSN: 2654-3257.
- Sari PJ. 2015. Studi awal histoteknik perfusi PBS-formalin dan gambaran histologi organ hepar, pankreas dan ginjal tikus

- strain *sprague dawley*. [Skripsi]. Jakarta: UIN Syarif.
- Setiawan A, Nachmed S, Asmara WI. 2013. Pertumbuhan dan perkembangan otak fetus mencit setelah induksi ochratoxin a selama periode organogenes. *Jurnal Biologi Papua*. vol 2(3).
- Singer, B.C., Nazaroff, W.M. February 2004. *Journal of Exposure Analysis and Environmental Epidemiology* 14(suppl 1): S71-S77. DOI:10.1031/jea.7500361.
- Susantiningi PA, Fiana DN, Carolia N. 2014. Pengaruh ekstrak daun sirsak (*Annona muricata* L) terhadap gambaran histopatologi jaringan paru tikus putih betina yang diinduksi karsinogen 7,12 dimethybenz (α) anhracene (DMBA) medical. *Journal of Lampung University*. vol (3): 9-7.
- Tursinawati Y, Noor Y, Findi WP. 2017. Gabaran hispatologi ventrikel kiri tikus yang diberi paparan rokok elektrik (Ends) dan konvensional. *Qanun Medika*. vol 1(2).
- Umukoro S, Mary A, Benneth B, Abayomi MA, Adegbuyi OA. 2019. Neurobehavioral effects of prolonged exposure to solid air freshener in mice. *Iranian Journal Toxicology*. vol 3: 45-51. <http://doi.org/10.32598/IJT.13.3.595.1>
- Yuningtyaswari Y, Dwitarsi V. 2012. Pengaruh paparan pengharum ruangan cair dan gel terhadap gambaran histology mukosa hidung *Rattus Norvegicus*. *Jurnal Mutiara Medika*. vol 12(1): 84-90.
- Yunus J, Dwi CRS. 2012. Efek neuroprotektif vitamin D3 terhadap jumlah sel purkinje cerebellum yang diinduksi etanol. *Jurnal Mutiara Medika*. vol 2(1).
- Yuningtyaswari Y, Haryani A. 2015. Pengaruh paparan pengharum ruangan cair dan gel terhadap gambaran histology pulmo pada tikus putih (*Rattus Norvegicus*). *Jurnal Pendidikan Dokter Mutiara Medika*. vol 15(1): 84-90.

ORIGINALITY REPORT

19%

SIMILARITY INDEX

16%

INTERNET SOURCES

8%

PUBLICATIONS

8%

STUDENT PAPERS

PRIMARY SOURCES

1	www.ndbbio.com Internet Source	2%
2	Submitted to National University of Ireland, Galway Student Paper	2%
3	Garuda.Kemdikbud.Go.Id Internet Source	1%
4	ejournal.unisba.ac.id Internet Source	1%
5	Muhammad Win Afgani, Retni Paradesa. "PISA-LIKE PROBLEMS USING ISLAMIC ETHNOMATHEMATICS APPROACH", Infinity Journal, 2021 Publication	1%
6	journals.physiology.org Internet Source	1%
7	repository.ubaya.ac.id Internet Source	1%
8	www.nature.com Internet Source	1%

9	Submitted to International Islamic University Malaysia Student Paper	1 %
10	worldwidescience.org Internet Source	1 %
11	Submitted to Oldham Sixth Form College Student Paper	1 %
12	jurnal.fmipa.unmul.ac.id Internet Source	1 %
13	my.clevelandclinic.org Internet Source	1 %
14	Putri C. Situmorang, Syafruddin Ilyas, Salomo Hutahaean, Rosidah, Risma D. Manurung. "ACUTE TOXICITY TEST AND HISTOLOGICAL DESCRIPTION OF ORGANS AFTER GIVING NANO HERBAL ANDALIMAN (Zanthoxylum acanthopodium)", Rasayan Journal of Chemistry, 2020 Publication	1 %
15	ejournal.uniks.ac.id Internet Source	1 %
16	Submitted to SDM Universitas Gadjah Mada Student Paper	1 %
17	journal.uin-alauddin.ac.id Internet Source	1 %

18 mail.scialert.net 1 %
Internet Source

19 www.com.ui.edu.ng 1 %
Internet Source

20 etheses.uin-malang.ac.id 1 %
Internet Source

Exclude quotes Off

Exclude matches < 1%

Exclude bibliography Off